

SARCOIDOSIS: A RARE CAUSE OF KLEINE-LEVINE-CRITCHLEY SYNDROME

K. Afshar, K. Engelfried, O.P. Sharma

Division of Pulmonary and Critical Care Medicine, Keck School of Medicine Los Angeles, CA

ABSTRACT. Hypothalamic sarcoidosis is a rare entity that can alter the hypothalamic-pituitary axis and induce various combinations of endocrine changes. We present a case of neurosarcoidosis with uncommon features of hypersomnolence and hyperphagia. Current strategies to increase awareness and prevention of the harmful effects of obesity require clinicians to be cognizant of potential disorders that produce these features. The mechanism, differential diagnosis and therapeutic options of this organic etiology are reviewed. (*Sarcoidosis Vasc Diffuse Lung Dis* 2008; 25: 60-63)

KEY WORDS: sarcoidosis, hypothalamus, mechanism of disease, polyphagia, hypersomnolence

In November 2003, this 28-year old Indian man noticed a dramatic increase in appetite. He became ravenous and gained more than 80 pounds in less than six months. His uncontrollable hyperphagia turned into a family crisis. Soon after he developed diabetes mellitus, dyspnea, and hypersomnia. In May 2004, his parents noted symptoms of cognitive changes, including difficulties with short-term memory, fatigue, confusion, irritability, and aggression. In June and July 2004, the patient was involved in two motor vehicle accidents; his parents were convinced sleepiness and poor concentration were the main reasons for the mishaps.

Physical examination revealed a morbidly obese man with a marked buffalo-hump and a plethoric, Cushingoid face. Neurologically, the mini mental status revealed a 27/30 (missed the date, country and 1 out of 3 on recall). His gait was wide base with

normal stride. The toe and heel gait were intact, but slightly unsteady with tandem.

A magnetic resonance image of the brain revealed extensive leptomeningeal enhancement, especially in the basal cisterns that extended up to the anterior hemispheric fissure and sylvian fissure (Fig. 1). The chest radiograph showed mediastinal and bilateral hilar adenopathy. A subsequent serum ACE level drawn measured at 33 micrograms/L. Mediastinal lymph node biopsy revealed a non-caseating granuloma, confirming the diagnosis of sarcoidosis. The acid fast stains and GMS stains were negative. No biopsies from the brain lesions were obtained, since adequate evidence was present to attribute the neurological derangements to neurosarcoidosis. A sleep polysomnography confirmed the presence of obstructive sleep apnea. A CPAP machine was provided, which the patient used inconsistently.

Hormones measurement included cortisol 12 micrograms/dL, thyroid stimulating hormone 0.122 mIU/L, follicular stimulating hormone 1.8 mIU/mL, and luteinizing hormone 1.6m IU/ml, and prolactin 10.7 ng/mL and hemoglobin A1c 8.9%.

The patient was given prednisone 40 mg/day. He had radiographic and clinical improvement on subsequent follow-up visits. Unfortunately, the pa-

Received: 17 April 2007

Accepted after Revision: 9 October 2007

Correspondence: Kamyar Afshar, DO

Division of Pulmonary and Critical Care Medicine,

University of Southern California

1200 North State Street, Room 11900

Los Angeles, CA 90033

Tel: 323-226-7923, Fax: 323-226-2793

E-mail: kafshar@usc.edu

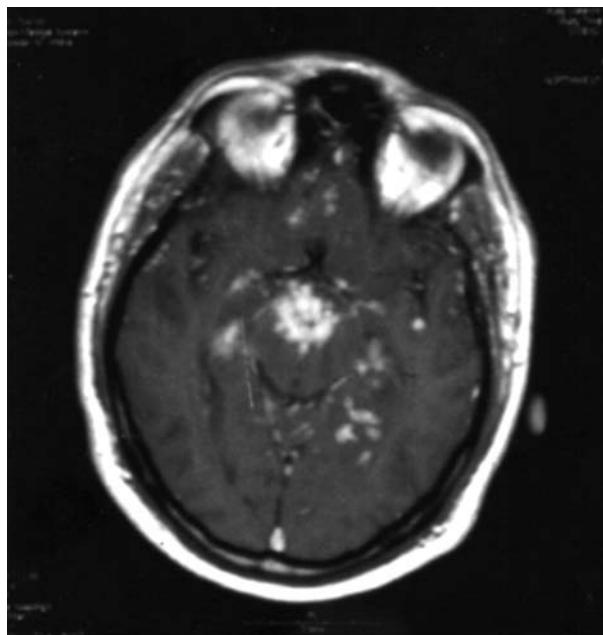


Fig. 1. MRI brain showing extensive leptomeningeal enhancement and involvement of the hypothalamus.

tient began experiencing multiple adverse effects of chronic steroid use, including worsened generalized fatigue, unilateral sharp headaches of moderate to severe intensity with associated visual hallucinations, difficulty to walk due to severe pain in both hips, uncontrollable hyperglycemia, and continued weight gain. As the steroid dose was tapered, the patient initially felt better, but weeks later he developed increased dyspnea on exertion and a decline in cognitive function. Azathioprine was then given as a steroid sparing agent.

COMMENT

In 1925, Kleine from Frankfurt reported 5 patients with periodic somnolence of various causes. In 1936, Levin, a New York psychiatrist drew attention to one very atypical case of periodic somnolence that was combined with excessive appetite. He suggested that a “syndrome of periodic somnolence and morbid hunger” represented a novel and specific entity. The eponym “Kleine-Levin syndrome was first time applied by Critchley who, in 1962, pointed to the salient features of this new syndrome: (1) limitation to the male sex; (2) an age-incidence between 15 and

25 years of age; (3) the presence of schizoid symptoms; (4) excessive intake of food was a manifestation of compulsive eating. He further proposed a new title for the syndrome, “periodic hypersomnia and megaphagia in adolescent males”. The entity soon became known as Kleine-Levin-Critchley syndrome.

In 1979, Critchley concluded that the nature of the syndrome remained obscure. He, however, suggested that the entity was, despite its psychiatric trapping, organic in nature (1).

What organic causes are responsible for Klene-Levine-Critchley syndrome? Multiple animal studies have shown that the electrolytic lesions of the ventromedial hypothalamus (VMH) produce a syndrome characterized by hyperphagia, adiposity, and heightened parasympathetic tone (2). These animal models gain weight regardless of whether they were placed in the sedentary or exercising group. Parkinson and Weingarten studied comparable effects of lesions on the ventromedial hypothalamic nucleus (VMN), perifornical hypothalamic knife (PFH) cuts, the ventromedial hypothalamus (VMH) lesions, or sham surgery (3). In the animals maintained on unrestricted feeding, VMH and PFH rats became hyperphagic, gained weight, and became obese. VMN rats on ad libitum diet did not become hyperphagic or gained excessive weight, but they develop an obesity characterized by an elevated level of carcass fat. Under strict feeding, both VMH and VMN rats became obese, but PFH rats did not. The VMH rats developed obesity whether they were on restricted or ad libitum regimens. This type of obesity is called metabolic obesity because it does not require a behavioral disturbance for its expression. There are obvious clinical implications of this dissociative animal model. Systemic disorders including granulomatous diseases, vasculitis, or ischemic lesions may cause either behavioral or metabolic obesity depending on whether they involve either the fiber system in the medial hypothalamus or cause injury to the ventromedial nucleus.

Unfortunately, the mechanisms for hypothalamic obesity remain obscure. Injury to the ventromedial hypothalamic region from a variety of insults, such as, trauma, surgery or malignancy has shown to produce signs and symptoms of obesity and hyperphagia (4-7). Celesia et al presented a case of hyperphagia and obesity secondary to hypothalamic in-

Table 1

Features	Localized CNS Granuloma	Systemic Sarcoidosis
Age	Any age	20-40 years old
High ACE levels	< 5%	> 60%
Hypercalcemia	Absent	Present in 13%
Organ involvement	Usually one organ	Multiple organs
Chest radiograph	Normal	Abnormal in 90%
BAL lymphocytes	Normal levels	Low levels
Delayed hypersensitivity	Normal	Depressed
Gallium body scan	Localized uptake	Multi-system uptake
Slit lamp examination	Normal	Positive in up to 20%

ACE = angiotensin converting enzyme; BAL = bronchoalveolar lavage

involvement due to astrocytoma (8). The brain biopsy revealed necrotic areas with astrocytes consistent with glioblastoma multiformae. Hyperphagia has been reported in systemic lupus erythematosus and a distinct entity called recurrent optic neuromyelitis with endocrinopathies (9, 10) but there are no reports of the syndrome occurring in bacterial or fungal granulomatous disorders. Sommer et al described a 42-year old woman with tetraparesis, diabetes insipidus, hyperphagia and memory loss (11). CSF examination showed lymphocytic pleocytosis; MRI revealed lesions consistent with granulomatous inflammation. There was no evidence of systemic manifestation or biopsy evidence of non-caseating granuloma. In another case by Vanhoof et al the patient with hypothalamic hypopituitarism, loss of visual fields and hyperphagia (12). There was no evidence of multisystem disease and no biopsy evidence of granulomatous disease. Thus the diagnosis of sarcoidosis was not firmly established by ATS/ERS/WASOG/ guidelines (13). These two patients at best remain excellent examples of local central nervous system sarcoid reaction (14).

Our case is only the only known case of multi-system biopsy proven sarcoidosis that developed polyphagia and hypersomnia due to hypothalamic infiltration.

Sarcoidosis is a multi-system granulomatous disease that can affect any organ. The etiology still remains unclear. It commonly affects the young between the ages of 20 to 40 years. Although, the pulmonary system is affected in approximately 90% of the patients, central nervous system may be involved in 5-15% of the patients. The most notable manifestations of CNS involvement include seizures, cognitive or psychiatric disorders, cranial nerve palsies,

neuritis, autonomic dysfunction and meningitis (15-18). Hypothalamic involvement is common (19-22). It is of interest that with such an evident hypothalamic involvement, more cases have not been observed with this association. Magnetic resonance imaging of the brain is a very sensitive diagnostic tool for locating the neurological involvement.

Corticosteroids are universally used to suppress inflammation of sarcoidosis. Prednisone at the stress dose of 1 mg/kg/day will acutely suppress inflammation in many patients. It should be tapered over 6-8 week-duration to a dose range of 10-25 mg/day. In a subset of patients; however, their symptoms tend to recur. Cytotoxic drugs are used as steroid sparing agents to control symptoms. Both steroids and the cytotoxic agents may have deleterious symptoms. There is no current approval for the use of infliximab in cases of sarcoid, let alone those manifesting neurologic involvement; however, case reports have shown that infliximab therapy is an effective alternative therapy (23). Remarkable clinical improvements are reported within a period of several months in patients with refractory sarcoid and those experiencing significant side effects from steroids or other immunosuppressive agents (24, 25). This patient is considered an ideal candidate for infliximab for the life-threatening manifestation of neurologic involvement and previous intolerance to standard therapy. Potential complications of this agent are reactivation of other granulomatous diseases, such as tuberculosis and histoplasmosis. Surgical options are limited. Neurosurgical resection has been reserved only for expanding mass lesions or mass lesions causing elevated intracranial pressures. Ventriculoperitoneal shunting is indicated and typically used for hydrocephalus.

REFERENCES

1. Critchley M. *The Divine Banquet of the Brain*. Raven Press, New York 1979, 167-71.
2. Heatherington A, Ranson S. Hypothalamic lesions and adiposity in rat. *Anat Rec* 1940; 78, 149-72.
3. Parkinson W, Weingarten H. Dissociative analysis of ventromedial hypothalamic obesity syndrome. *Am J Physiol* 1990; 259, R289-R335.
4. Barutca S, Turgut M, Meydan N, Ozsunar Y. Subthalamic Nucleus Tumor Causing Hyperphagia. *Neurol Med Chir (Tokyo)* 2003; 43: 457-60.
5. Pinkney J, Wilding J, Williams G, MacFarlane I. Hypothalamic obesity in humans: what do we know and what can be done? *Obes Rev* 2002; 3 (1): 27-34.
6. Coffey RJ. Hypothalamic and basal forebrain germinoma presenting with amnesia and hyperphagia. *Surg Neurol* 1989; 31 (3): 228-33.
7. Haugh RM, Markesbery WR. Hypothalamic astrocytoma. Syndrome of hyperphagia, obesity, and disturbances of behavior and endocrine and autonomic function. *Arch Neurol* 1983; 40: 560-3.
8. Celesia GG, Archer CR, Chung HD. Hyperphagia and obesity. Relationship to medial hypothalamic lesions. *JAMA* 1981; 246: 151-3.
9. Chong Yew Hock, Cheong I. Transverse myelopathy and hyperphagia in systemic lupus erythematosus: a case report. *Med J Malaysia* 1985; 40 (4): 333-4.
10. Vernant JC, Cabre P, Smadja D, Merle H, Caubarrere I, Mikol J, Poser CM. Recurrent optic neuromyelitis with endocrinopathies: a new syndrome. *Neurology* 1997; 48 (1): 58-64.
11. Somner N, Weller M, Petersen D, Wietholter H, Dichgans J. Neurosarcoidosis without systemic sarcoidosis. *Eur Arch Psychiatry Clin Neurosci* 1991; 240 (6): 334-8.
12. Vanhoof J, Wilms G, Bouillon R. Hypothalamic hypopituitarism with hyperphagia and subacute dementia due to neurosarcoidosis: case report and literature review. *Acta Clin Belg* 1992; 47 (5): 319-28.
13. ATS/ERS/WASOG Committee Statement on Sarcoidosis. *Am J Respir Crit Care Med* 1999; 160: 736-55.
14. Hoitsma E, Faber CG, Drent M, Sharma OP. Neurosarcoidosis: A clinical dilemma. *The Lancet Neurology* 2004; 3.
15. Stern BJ, Krumholz A, Johns C, Scott P, Nissim J. Sarcoidosis and its neurological manifestations. *Arch Neurol* 1985; 42: 909-17.
16. Sharma OP, Sharma AM. Sarcoidosis of the nervous system: a clinical approach. *Arch Intern Med* 1991; 151: 1317-21.
17. Kidd D, Beynon H. The neurological complications of systemic sarcoidosis. *Sarcoidosis Vasculitis and Diffuse Lung Diseases* 2003; 20: 8-94.
18. Stern BJ. Neurological complications of sarcoidosis. *Curr Opin Neurol* 2004; 17: 311-6.
19. Pavese P, Brion JP, Chabre O, Fauconnier J, Pasquier B. Neurologic involvement in sarcoid. Federation of systemic diseases of Grenoble. *Presse Med* 1999; 28 (4): 168-72.
20. Gullapoli, D and Phillips, LH. Neurologic manifestations of sarcoidosis. *Neurol Clin* 2002; 20: 1-17.
21. Fels C, Riegel A, Javaheripour-Otto K, Obenauer S. Neurosarcoidosis: findings in MRI. *Clinical Imaging* 2004; 28 (3): 166-9.
22. Spencer TS, Campellone JV, Maldonado I, Huang N, Usami O, Reginato AJ. Clinical and magnetic resonance imaging manifestations of neurosarcoidosis. *Semin Arthritis Rheum* 2005; 34 (4): 649-61.
23. Doty JD, Mazur JE, Judson MA. Treatment of Sarcoidosis with Infliximab. *Chest* 2005; 127: 1064-71.
24. Roberts SD, Wilkes DS, Burgett RA, Knox KS. Refractory Sarcoidosis Responding to Infliximab. *Chest* 2003; 124: 2028-31.
25. Saleh S, Ghodsian S, Yakimova V, Henderson J, Sharma OP. Effectiveness of infliximab in treating selected patients with sarcoidosis. *Respiratory Medicine* 2006; 100: 2053-9.